

# Automated Detection and Classification of Glaucoma from Eye Fundus Images: A Survey

Prof. Syed Akhter Hussain<sup>1</sup>, Dr. Holambe A. N<sup>2</sup>

*Head Department of Computer science Aditya College of Engineering, Beed  
Maharashtra India<sup>1</sup>,*

*Head Department of Computer science College of Engineering, Osmanabad  
Maharashtra India<sup>2</sup>*

**Abstract**—the identification of eye diseases in retinal image is the subject of several researches in the field of medical image processing. this research proposed a computerized aid diagnosis system to help specialists by displaying useful information such as the location of abnormalities in fundus images This paper is a survey of techniques for Automatic detection of retina image now a days it is plying a vital role in screening tool. This procedure helps to detect various kind of risks and diseases of eyes. Identification of Glaucoma using fundus images involves the measurement of the size, shape of the Optic cup and Neuroretinal rim One of the most common diseases which cause blindness is glaucoma. Early detection of this disease is essential to prevent the permanent blindness. Screenings of glaucoma based on digital images of the retina have been performed in the past few years. Several techniques are there to detect the anomaly of retina due to glaucoma. The key image processing techniques are image registration, image fusion, image segmentation, feature extraction, image enhancement, morphology, pattern matching, image classification, analysis and statistical measurements. The main idea behind this paper is to illustrate a system which is mainly based on image processing and classification techniques for automatic detection of glaucoma by comparing and measuring different parameters of fundus images of glaucoma patients and normal patients.

**Keywords**—Glaucoma, Cup to disk ratio, Neuroretinalrim Fundus Image, ISNT (inferior, superior, nasal, temporal quadrants), ANN, K-Means Clustering, Thresholding, CDR, ISNT, SVM, Bayesian.

## 1. INTRODUCTION

Glaucoma is a chronic eye disease that leads to vision loss. Glaucoma is caused due to the increase in intraocular pressure of the eye. The intraocular pressure increases due to malfunction or malformation of the drainage system of the eye. The anterior chamber of the eye is the small space in the front portion of the eye. A clear liquid flow in and out of the chamber and this fluid is called aqueous humor. The increased intraocular pressure within the eye damages the optic nerve through which retina sends light to the brain where they are recognized as images and makes vision possible. Glaucoma is a condition that causes damage to your eye's optic nerve and gets worse over time. It's often associated with a build-up of pressure inside the eye. Figure 1 shows normal eye and glaucoma affected eye. Glaucoma tends to be inherited and may not show up until later in life. The increased pressure, called intraocular pressure, can damage the optic nerve, which transmits images to the brain. If damage to the optic nerve

from high eye pressure continues, glaucoma will cause permanent loss of vision. Without treatment, glaucoma can cause total permanent blindness within a few years.

Therefore early detection of this disease is essential to prevent the permanent blindness. There are several automated glaucoma detection techniques already available. In this study, we are trying to do a review of all those available techniques. Each of the techniques has some advantages as well as disadvantages. Based on this study, we can determine which technique can be applied in which scenario to obtain the optimal result.

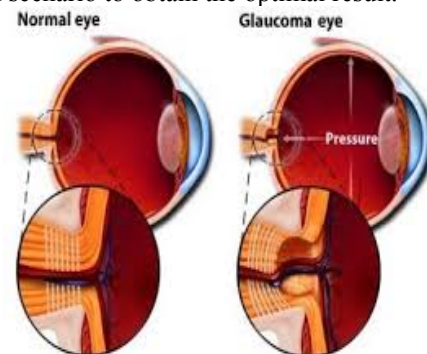


Figure 1 Medical image of normal and affected eye.

### 1.1 Types of Glaucoma

There are several types of glaucoma. The two main types are open-angle and angle-closure. These are marked by an increase of intraocular pressure (IOP) or pressure inside the eye.

1) Open-Angle Glaucoma: It is the most common form of glaucoma, accounting for at least 90% of all glaucoma causes: Is caused by the slow clogging of the drainage canals, resulting in increased eye pressure it has a wide and open angle between the iris and cornea it develops slowly and is a long life condition its symptoms and damages are not noticed. Open-angle means that the angle where the iris meets the cornea is as wide and open as it should be Open-angle glaucoma is also called primary or chronic glaucoma.

2) Angle-Closure Glaucoma: It is a less common form of glaucoma: Is caused by blocked drainage canals, resulting in a sudden rise in intraocular pressure it has a closed or narrow angle between the iris and cornea Develops very quickly it has symptoms and damage that are usually very noticeable Demands immediate medical attention. It is also called acute glaucoma or narrow angle glaucoma.

Unlike open-angle glaucoma, angle- closure glaucoma is a result of the angle between the iris and cornea closing.

3) Normal Tension Glaucoma: It is also called as low-tension or normal-pressure glaucoma. It is a form of glaucoma in which damage occurs to the optic nerve without eye pressure exceeding the normal range (10-20 mmHg).

4) Congenital Glaucoma: This type of glaucoma occurs in babies when there is incorrect or incomplete development of the eye's drainage canals during the parental period. This is a rare condition that may be inherited. It is also referred as childhood glaucoma, pediatric or infantile glaucoma. It is usually diagnosed within the first year of baby life [43].

### 1.2 Tests for Glaucoma

There are five factors should be checked before making a glaucoma diagnosis.

1) Tonometry: It measures the pressure within the eye. During tonometry, eye drops are used to numb the eye. Then a doctor uses a device called a tonometer to measure the inner pressure of the eye. A small amount of pressure is applied to the eye by a tiny device or by a warm puff of air.

2) Ophthalmoscopy: This diagnostic procedure helps the doctor to examine the optic nerve for glaucoma damage. Eye drops are used to dilate the pupil so that the doctor can see through the eye to examine the shape and color of the optic nerve. The doctor will then use small device with a light on the end to light and magnify the optic nerve.

3) Perimetry: It is a visual field test that produces a map of the complete field of vision. This test will help a doctor determine whether the vision has been affected by glaucoma. During this test, the patient will be asked to look straight ahead and then indicate when a moving light passes the peripheral vision. This helps to draw a map of the vision.

4) Gonioscopy: This diagnostic exam helps to determine whether the angle where the iris meets the cornea is open and wide or narrow and closed. During the exam, eye drops are used to numb the eye. A hand-held contact lens is gently placed on the eye. This contact lens has a mirror that shows the doctor if the angle between the iris and cornea is closed and blocked or wide and open.

5) Pachymetry: It is a simple, painless test to measure the thickness of the cornea- the clear window at the front of the eye. A probe called a pachymeter is gently placed on the front of the eye to measure cornea's thickness. Pachymetry can help the diagnosis, because corneal thickness has the potential to influence eye pressure readings. With this measurement, the doctor can better understand the IOP reading and develop a treatment plan [41, 42].

## 2. LITRATURE REVIEW

Zhuo Zhang et al. [1] proposed a convex hull based ellipse optimization algorithm for a more accurate detection of neuro-retinal optical cup. Comparing with the state-of-the-art ARGALI system, the new approach achieves a better CDR value calculation, which results to more accurate Glaucoma Diagnosis. The good performance of the new approach leads to a large scale clinical evaluation involving 15 thousand patients from Australia and Singapore.

Huiqi Li et al. [2] proposed algorithms to extract features automatically and robustly in color fundus images. PCA is employed to locate optic disk. A modified ASM is proposed in the shape detection of optic disk. A fundus coordinate system is established based on the fovea localization. An approach to detect exudates by the combined region growing and edge detection is proposed. The success rates of disk localization, disk boundary detection, and fovea localization are 99%, 94%, and 100% respectively. The sensitivity and specificity of the exudates detection are 100% and 71% correspondingly. The success of the proposed algorithms can be attributed to the utilization of the model-based methods. The satisfactory feature detection could make the automatic analyzing system become more reliable.

Archana Nandibewoor et al. [3] proposed the early detection of glaucoma can be done in this method. An algorithm is proposed in such a way that any disorder found inside the eye with respect to color, an immediate action is taken. By keeping a standard color as reference, the patient's eye color is matched. If this patients eye color is darker then the reference image then the result is displayed as positive. Also the percentage of glaucoma affected is given. The risk involved in losing the eye sight is decreased due to the early detection and prevents the human from virtual impairers. Where an increase in the formation of color detects the glaucoma.

Inoue et al. [4] developed a glaucoma screening technique using super pixel classification on optic disc and optic cup segmentation. In optic disc segmentation, histograms were utilized to classify each super pixel as disc or non-disc. The quality of the automated optic disc segmentation is calculated using a self-assessment reliability score. For optic cup segmentation, along with the histograms, the location information is also included to boost up the performance. In this proposed segmentation approach a database of 650 images was used with optic disc and optic cup boundaries which had been manually marked by professionals. The results showed an overlapping error of 9.5% and 24.1% in disc and cup segmentation, respectively. Lastly the cup to disc ratio for glaucoma screening was computed.

Bock et al. [5] developed an automated glaucoma classification system that does not at all depend on the segmentation measurements. They had taken a purely data-driven approach which is very useful in large-scale screening. This algorithm undertakes a standard pattern recognition approach with a 2-stage classification step. In this study, various image-based features were analyzed and integrated to capture glaucomatous structures. There

are certain disease independent variations such as size differences, illumination in homogeneities and vessel structures which are removed in the preprocessing phase. This system got 86% success rate on a data set of 200 real images of healthy and glaucomatous eyes.

M muthu rama krishnan et al. [6] proposed a new automated glaucoma diagnosis system using a combination of HOS, TT, and DWT features extracted from digital fundus images. The system, uses an SVM classifier (with polynomial kernel order 2), was able to detect glaucoma and normal classes with an accuracy of 91.67%, sensitivity of 90%, and specificity of 93.33%. This classification efficiency may even be further improved using images with a broader range of disease progression, better features, and robust data mining algorithms. In addition, we propose an integrated index, which is composed of HOS, TT, and DWT features. The GRI is a single feature which distinguishes normal and glaucoma fundus images, Hence; it is a highly effective diagnostic tool which may help clinicians to make faster decisions during mass screening of retinal images. The proposed system is cost effective, because it integrates seamlessly with digital medical and administrative processes and incorporates inexpensive general processing components. Therefore, the glaucoma detection system can be used in mass screening where even a modest cost reduction, in the individual diagnosis, amounts to considerable cost savings. Such cost savings may help to eliminate suffering, because the money can be used to increase the pervasiveness of glaucoma screening or it can be used anywhere else in the health service, where it is even more effective.

Grau et al. [7] proposed a new segmentation algorithm, depending on the expectation-maximization. This algorithm used an anisotropic Markov random field (MRF). In this study, structure tensor had been used to characterize the predominant structure direction as well as spatial coherence at each point. This algorithm had been tested on an artificial validation dataset that is similar to ONH datasets. It has shown significant improvement over an isotropic MRF. This algorithm provides an accurate, spatially consistent segmentation of this structure.

Acharya et al. [8] developed an automated glaucoma detection system by combining the texture and higher order spectra (HOS) features obtained from fundus images. Naive Bayesian, Support vector machine, random-forest classifiers and sequential minimal optimization are used to perform supervised classification. After z-score normalization and feature selection, the results reveal that the texture and HOS based features. When these features are combined with a random-forest classifier it performs much better than the other classifiers. This method correctly diagnoses the glaucoma images with 91% accuracy

Joshi et al. [9] purposed an automated OD parameterization technique An OD segmentation technique is developed which works by integrating the information of local images around each point of interest in multidimensional feature space. This technique is quite robust against any form of variations found in the OD

region. They utilized a cup segmentation technique depending on anatomical information such as vessel bends at the cup boundary, which is quite vital as considered by glaucoma experts. The bends in a vessel can be easily detected by utilizing a region of support concept, which helps in selecting the right scale for analysis. In this study, a multi-stage strategy is used to find a reliable subset of vessel bends called r-bends, which is followed by a local spline fitting in order to find the desired cup boundary.

Cheng et al. [10] proposed a new technique for glaucoma detection based on RetCam. Wich is used in imaging modality that captures the image of iridocorneal angle. The manual grading and analysis of the RetCam image is quite a time consuming process but it gives expected output. They developed an intelligent system for analysis of iridocorneal angle images, which can distinguish between open angle glaucoma and closed angle glaucoma automatically and which consume less time and give expected result .

Vermeer et al. [11] proposed a model for detecting the change in images. This methodology depends on image set of 23 healthy eyes and includes colored noise, incomplete cornea and masking is done by the retinal blood vessels. This system uses two more methodologies for tracking progression by taking up one or two follow-up visits into the account. Then they are tested on these simulated images. Both of these methods are depending on Student's t-tests, anisotropic filtering and morphological operations. The images simulated by this technique are visually pleasing and also show statistical properties to the real images. This results in optimizing the detection methods. The results reveal that tracking the progression depending on two follow-up visits marks a great improvement in sensitivity without affecting the specificity favorably.

Huang et al. [12] developed an automated classifier based on adaptive neuro-fuzzy inference system (ANFIS) Stratus optical coherence tomography (OCT) technique was used for calculation of glaucoma variables (optic nerve head topography, retinal nerve fiber layer thickness). Decision making was performed in two stages: feature extraction using the orthogonal array and the selected variables were treated as the feeder to adaptive neuro-fuzzy inference system (ANFIS), which was trained with the back-propagation gradient descent method in combination with the least squares method. With the Stratus OCT parameters used as input, receiver operative characteristic (ROC) curves were generated by ANFIS to classify eyes as either glaucomatous or normal. The mean deviation was  $-0.67 \pm 0.62$  dB in the normal group and  $-5.87 \pm 6.48$  dB in the glaucoma group. The inferior quadrant thickness parameter was used for distinguishing between normal and glaucomatous eyes.

Hatanaka et al. [13] proposed a technique for detection of glaucoma utilizing a vertical cup-to-disc ratio. The proposed method tries to measure the cup-to-disc ratio using a vertical profile on the optic disc. After that the blood vessels of the disc were removed from the image. Then canny edge detection filter was used for detection of the edge of optic disc. The edge of the cup area on the vertical profile was calculated by the threshold method. as

a final point, the vertical cup-to-disc ratio was found out. In this study, they also presented a method for recognizing glaucoma by calculating C/D ratio. The method correctly identified 80% of glaucoma cases and 85% of normal cases.

L'aszl'o G. Ny'ul [14] devised a novel automated glaucoma classification technique depending on image features from fundus photographs. First at all size differences non uniform illumination and blood vessels are eliminated from the images. Then extraction of the high dimensional feature vectors is done. Finally compression is done using PCA and the combination before classification with SVMs takes place. The Glaucoma Risk Index (GRI) produced by the proposed system with a 2-stage SVM classification scheme achieved 86% success rate. This is analogous to the performance of medical experts in detecting glaucomatous eyes from such images. Since GRI is computed automatically from fundus images.

Pruthi et al. [15] developed an automated glaucoma detection system. The system takes as input a fundus image. In the preprocessing stage, illumination correction and blood vessel removal takes place. After the analysis of entire image, a small square having 360 X 360 pixels is taken around the brightest region is denoted as ROI. Feature extraction is done from the images. In this method the features are extracted from optic disc and optic cup. The diameter of cup and optic disc is used for calculating Cup to disc ratio. It is extracted from the segmented optic disc and cup. The classifiers namely SVM, Back Propagation Neural Network, ANFIS are used to differentiate between normal and abnormal cases of glaucoma. ANFIS, SVM and Back Propagation had achieved accuracy of 97.77%, 98.12% and 97.35% respectively.

Mary et al. [16] devised a technique for glaucoma detection where optic disc segmentation is done by pyramidal decomposition with the help of Hough transformation it guaranteed to converge though it's very sensitive to noise which carried out on the retinal images for better performance than other algorithms. They have proposed a model approach using discriminate analysis which has shown an improvement over the rest.

Sobi Nazi et al. [17] proposed a system where the main technique is to identify the cup-to-disc ratio (CDR). The CDR was calculated by taking the ratio between the area of optic cup and disc.  $CDR > 0.3$  indicates glaucoma and  $CDR \leq 0.3$ , is considered as normal image. They examine the mean square error (MSE) pixel signal to noise ratio (PSNR) and signal to noise ratio (SNR) to quantify the performance the pre-processing algorithms. The algorithm for the earlier identification of Glaucoma by estimating CDR was developed in this paper. The optic disc was segmentation is done using the three methods first edge detection method second optimal Thresholding method and third manual threshold analysis are. For the cup threshold level-set method is evaluated. The performance of various methods was evaluated by comparing the CDR. It was found that the manual threshold method and edge detection method provides

better estimation of CDR. The method has been applied to nearly forty images and the CDR was correctly identified.

Abirami et al. [18] devised a novel automated Glaucoma detection system. in proposed system detection and classification is performed from fuzzy min-max neural network based on Data-Core (DCFMN) deals with the Image obtained from Stratus Anterior Segment Optical Coherence Tomography (AS-OCT). Data-core fuzzy min-max neural network (DCFMN) depicts strong robustness as well as high accuracy in classification. DCFMN contains two classes of neurons: classifying neurons (CNs) and overlapping neurons (OLNs). CNs is used to classify the patterns of data. The OLN can handle all kinds of overlap in different hyper boxes. The membership function of Overlapping Neurons (OLNs) deals with the relative position of data in the hyper boxes. This algorithm is performed on a batch of 39 anterior segment- Optical Coherence Tomography (AS-OCT) images. This proposed system gives classification rate of 97%.

Chandrika et al. [19] adopted a technique for automated Glaucoma diagnosis. In this technique optic disc identification is performed on retinal images for calculating CDR they first performed Thresholding then image segmentation is performed using k-means clustering and Gabor wavelet transform. Then optic disc and cup boundary smoothing is performed using different morphological features. If the CDR ratio exceeds 0.3 it indicates high Glaucoma for the tested patient.

Aquino et al. [20] presented a new Optic disc (OD) detection technique which is an imperative step for automated diagnosis of Glaucoma. In this paper they developed a new template-based approach for differentiating the OD from digital retinal images. For circular OD boundary approximation they use morphological, edge detection techniques followed by the Circular Hough Transform. A pixel located within the OD is taken as initial information. Glaucoma is identified by recognizing the changes in depth, shape and color that it produces in the OD. Thus, this technique used segmentation as well as analysis to detect Glaucoma automatically.

Kumar et al. [21] proposed an algorithm for glaucoma detection. In this algorithm, active contours are used for segmentation and feature extraction of an image. The initial point of interested feature is determined accordingly. After that masking is done by cropping the region of interest. Finally calculation of the open angle of the anterior chamber is conducted. If the open angle is found to be greater than threshold angle, the eye is diagnosed as normal eye. Otherwise, it is diagnosed to be diseased eye.

Anusorn et al. [22] presented a method to calculate the CDR automatically from fundus images. The image pre-processing is the first step to localize the optic disc and cup. The optic disc is extracted using an edge detection approach and a variation level-set approach separately. The optic cup is then segmented using a color component analysis method and threshold level-set method. After obtaining the contours, an ellipse fitting step is introduced to sharpen the obtained results. Using 44 images, the

performance of this approach is evaluated using the proximity of the calculated CDR to the manually graded CDR. The results indicating that our approach provides 89% accuracy in glaucoma analysis.

Pachiyappan et al. [23] proposed a technique for Glaucoma diagnosis utilizing fundus images of the eye and the optical coherence tomography (OCT). The Retinal Nerve Fiber Layer (RNFL) can be generally classified into two types anterior boundary (top layer of RNFL), the posterior boundaries (bottom layer of RNFL) it was also based on the distance in between the two boundaries. Glaucomatous and Non-Glaucomatous classification was done using the thickness of the nerve fiber layer which is nearly 105  $\mu\text{m}$ . This approach provided optical disk detection with 97.75% accuracy.

Preeti Kailas Suryawanshi [24] proposed a technique which extracted ROI from retinal images. Optic disc segmentation is performed on the extracted ROI in order to detect the disc boundary using optimal color channel. Optic disc boundary smoothing is performed using ellipse fitting for capturing near perfect shape of the disc. Optic cup segmentation is also performed. After the cup boundary detection, ellipse fitting is again employed to eliminate some of the cup boundary's sudden changes in curvature. Ellipse fitting becomes especially useful when portions of the blood vessels in the neuro-retinal rim are incorporated within the detected boundary. The CDR is automatically obtained based on the height of detected cup and disc. If the cup to disc ratio exceeds 0.3 then it indicates the abnormal condition that is the presence of glaucoma.

K. Narasimhan et al. [25] proposed a new methodology for the detection of glaucoma based on two imperative features CDR and ISNT ratio. K-means clustering is recursively applied to ROI to localize the optic disc and optic cup region. An elliptical fitting technique is used to calculate the CDR values. The blood vessels inside the optic disc are extracted by local entropy Thresholding and four different masks are used to determine the ISNT ratio. CDR and ISNT ratio are calculated. Then they carried out a performance of the proposed algorithm on three different classifiers. Experiments suggest that the maximum classification rate of 95% for glaucoma can be achieved when using the SVM classifier.

Neelapala Anil Kumar et al. [26] proposed a technique for automated detection of glaucoma in eye by using angle open distance 500 calculations. This technique is a 3 step methodology. In the first step, for effective anterior chamber segmentation they use features of the ultrasound images i.e. contrast, resolution and clarity is. In second step, classification is performed to eliminate the unwanted image. Then they crop the anterior chamber region and the reference axis is located. In third step on the basis of anterior chamber angle for finding out whether the eye is affected by glaucoma or not focuses. This algorithm is able to correctly diagnose glaucoma in 97% of the cases.

Noor Elaiza et al. [27] proposed a method on color range analysis, green is found to be a good contrast and

bright image. Red is found to be the worst image as it has low contrast and bright image. The survey among the ophthalmologists shows an agreement of results in a green image analysis but the results highly varied in the blue image. It is also found that the green image segmentation has better image quality than the gray image. The red images are rated as poor quality. In the threshold analysis, the green and gray images are at par. The red channel image is considered as poor quality image. Meanwhile, the blue channel image shows the lowest percentage of poor quality image. The variability of Gray channel quality grading is the smallest among all channels, while the highest variability is recorded in the green channel. The blue channel shows a normal distribution of pixel value, but due to its low contrast, both ophthalmologists and threshold graded as low quality image.

Priya kumbhare et al. [28] proposed an automatic glaucoma diagnosis system that combines texture and HOS features extracted from fundus images for diagnosis. They found that the texture and HOS-based features were clinically significant, i.e., these features had a low p-value, which means that there is more chance that these features have very different values for the normal and abnormal classes and hence better discriminate the two classes. Therefore they used these features for classification. The performances of four supervised classifiers were evaluated. They found that the random-forest classifier combined with zscore normalization and feature-selection methods, performed the best among the four classifiers with a classification accuracy of more than 91%.

Anantha Vidya Sagar et al. [29] proposed a novel system for the automatic detection of important anatomical structures such as OD, macula and blood vessels has been proposed in this paper. Robustness and accuracy of the system have been evaluated on a database of 100 images. The results are encouraging and these methods contribute to our overall goal of development of a system for the automated screening of Diabetic Retinopathy in medical camps.

Urja Zade et al. [30] proposed a technique for glaucoma assessment which allows derivation of various geometric parameters of the OD and Incremental cup segmentation method using 3D interpolation. The best answer for eye disease assessment was within the form of 2 segmentation strategies for OD and cup. A novel, active contour model is bestowed to urge strong OD segmentation. This has been achieved by enhancing the CV model by together with image info at the support domain around each contour purpose. A horny facet of the extension is the strengthening of region-based active contour model by the integration of data from multiple image feature channels. The obtained results will show that technique captures OD boundary during a unified manner for each traditional and difficult cases while not imposing any form constraint on the segmentation result, in contrast to the sooner strategies. In cup segmentation, it's observed that boundary estimation errors area unit principally in regions with no depth cues that is in keeping with the high inter-observer variability in these regions.

S.Kavitha et al. [31] proposed K Means clustering technique which focuses on the pallor information at each pixel thereby enabling rapid clustering and achieves a very good accuracy in detecting the optic cup. It is simple and easy to implement an unsupervised method rather than a supervised approach. Hill climbing technique and k means clustering provides a promising step for the accurate detection of optic cup boundary. Vertical CDR or superior or inferior rim area parameters may be more specific in identifying the Neuroretinal rim loss along the optic disc compared to an overall cup-to-disc diameter ratio. Textural features are considered in this work in order to effectively detect glaucoma for the pathological subjects. A hybrid method involving textural features along with CDR, Neuroretinal Rim area calculation provides an efficient means to detect glaucoma. ANFIS achieves good classification accuracy with a smaller convergence time compared to Neural network classifiers. Performance of the proposed approach is comparable to human medical experts in detecting glaucoma. Proposed system combines feature extraction techniques with segmentation techniques for the diagnosis of the image as normal and abnormal. The method of considering the Neuroretinal rim width for a given disc diameter with the textural features can be used as an additional feature for distinguishing between normal and glaucoma or glaucoma suspects. Progressive loss of Neuroretinal rim tissue gives an accurate result to detect early stage of glaucoma with a high sensitivity and specificity.

Asma Mansour et al. [32] proposed a method of automatic detection of OD two methodologies one to locate the OD based on a PCA and another one to segment its boundary based on RSF. Then, early detection of exudates is very important in the diagnosis of ocular diseases, they have projected an approach which combines coarse and fine segmentation to obtain final detection of this kind of abnormalities.

Sheeba O. et al. [33] proposed a method for training and simulating artificial neural network to detect the presence of glaucoma and classify the disease as mild, severe and normal. The various parameters are easily extracted using Matlab and compared with standard values using neural network. The artificial neural network makes the Glaucoma detection accurate and adaptive. The advantage of the system is simplicity of operation. This software intended to help the doctors in their decision making process. To make this more user friendly graphical user interface is also given which makes the handling of this tool very simple.

Darsana S et al. [34] proposed technique in which they analyzed three sections. In the first section the performance of image based classification is analyzed. A total of 70 images are tested using the trained SVM which include 25 glaucomatous image and 45 normal images. Out of 70 images 67 images are classified correctly. The performance analysis is done by calculating sensitivity, specificity and accuracy. The results obtained are 97.7% sensitivity, 92% specificity and 95.7% accuracy. The performance of risk calculator is analyzed in the second section. Risk calculator effectively calculates the score for

every set of data inputs assuring high accuracy. Finally the combined glaucoma risk analysis is analyzed in the third section. The classification accuracy of this stage is a clear reflection of above stages. The risk labeled to each patient at this classification level will be a valuable reference for the clinicians for their further assessment.

S.Kavitha et al. [35] proposed algorithms for the identification of Glaucoma by estimating CDR were developed. ROI based segmentation is proposed to localize optic disk, which is estimated by using contour method exactly, when compared with other methods even though the image is in low contrast. The optic cup was segmented using the component analysis and the threshold methods separately. The performance of various methods was evaluated using the proximity of the calculated CDR to the clinical CDR. It was found that ROI, combined with the component Analysis method provides the better estimation of CDR.C/D ratio does not take into consideration the diameter of the disc and hence it is prone to give false positive and false negative impressions. The proposed work focuses on how much the Neuroretinal rim tissue is present. By categorizing the discs as small, medium or large, the expectation of rim thickness can be adjusted. This reduces the misclassification based on the disc size. It also takes into consideration the focal loss of rim tissue. Neuroretinal rim area evaluation may increase the value in Clinic practice for automatic screening of early diagnosis of Glaucoma. The results presented in this paper indicate that the features are clinically significant in the detection of glaucoma.

S. Sekhar et al. [36] The proposed technique was tested on the DRIVE database of retinal images this consists of 40 fundus images of dimensions 768×584, captured by a Canon CR5 non-mydratic 3CCD camera with a 45o field of view (FOV). These images contain both normal (healthy) and abnormal retinas. In this study, 36 of these images were used (4 images have been excluded for not having visually-detectable optic disks). The performance of the optic disk localization was evaluated based on the determined optic disk location with regard to an expert. Proposed method is capable of localizing the optic disk correctly for 34 of these images (success rate of 94.4%). method is able to detect the fovea in all of these 34 images with a success rate.

K.Kavitha et al. [37] proposed a glaucoma screening for optic disc and optic cup segmentation for the area under curve (AUC) of the ROC curves by various cup segmentation methods. Therefore, the AUC significantly larger than IOP, threshold, r-bend, ASM, and regression methods. The results show smaller CDR errors in CDR measurement and higher AUC in glaucoma screening by the proposed method. The proposed disc and cup segmentation methods achieve an AUC of 0.800,0.039 lower than AUC of 0.839of the manual CDR computed from manual disc and manual cup. In the results for the SCES dataset, the proposed method achieves AUC 0.822 in the screening SCES data, which is much higher than 0.660 by the currently used IOP measurement discussions with clinicians, the accuracy is good enough for a large-scale glaucoma.

Chalinee Burana-Anusornl et al. [38] proposed a method to calculate the CDR automatically from fundus images. The optic disc is extracted using an edge detection approach and a variation level-set approach individually. The optic cup is then segmented using a color component analysis method and threshold level-set method. After obtaining the contours, an ellipse fitting step is introduced to smoothen the obtained results. The performance of this approach is evaluated using the proximity of the calculated CDR to the manually graded CDR. The results indicate that our approach provides 89% accuracy in glaucoma analysis. As a result, this study has a good prospective in automated screening systems for the early detection of glaucoma.

Subi.P .P [39] proposed super pixel classification based methods for disc and cup segmentations for glaucoma screening and an approach to the quick detection and extraction of macula from the images of human retina. In disc segmentation, HIST and CSS balance each other. CSS responds to blobs and provides better differentiation between PPA and discs compared with histograms. Histograms with the contrast enhancement conquer the limitation of CSS due to distinguish variations. Reliability score is an important indicator of the automated results. In this research, disc segmentations with  $r \geq 0.85$  is likely to indicate good cases. For lower ones, it is likely that the results are inaccurate, even though the deformation in the last step might still find a good result in some situations. In cup segmentation, the benefit of CSS is even larger than that in disc segmentation, because the color change from cup to Neuroretinal rim is much smaller. Therefore, the uneven illumination becomes a large noise affecting the cup segmentation. The CSS computed from the centre surround difference is less sensitive. It is important to point out that the proposed super pixel classification is used as an initialization for deformable models. Macula segmentation is of paramount importance in developing automated diagnosis expert system for Doctor's.

A. Iyyanarappan et al. [40] proposed wavelet-based texture feature for that wavelet-based texture set has been used because the texture feature set is made up of the energy of sub images. Wavelet transform are very proficient tools for Feature extraction and they are very Successfully used in biomedical image processing. Classification technique is developed and based on automatically detect whether glaucoma is present or not. DWT Features gives maximum classification accuracy of 95% and it is quick, easy to operate, non-invasive and inexpensive.

### 3. CONCLUSION

This research survey paper depicts many works related to automated glaucoma detection. Lowering eye pressure in glaucoma's early stages slows down the progression of the disease and helps save vision Through the extensive literature review carried out it has been observed that though various methods for detection of glaucoma have been carried out there is still a need and scope to develop a

Computer Aided System which can not only help diagnose Glaucoma but would also help in checking the progression of the disease so that its growth can be restricted if not prevented. Lot of recent research is being carried for detection of Glaucoma using fundus images, but still detection of progression of Glaucoma in patient remains to be researched. In future, we need to develop more accurate, robust as well as affordable automated techniques for glaucoma detection so that the benefits are passed on the poorest of poor people. Once glaucoma is correctly diagnosed then they can take proper medicine or undergo surgery in a timely manner to avoid total blindness.

### ACKNOWLEDGMENT

Very Special Thanks to Dr.Imran Khan Pathan Milliya College of computer science beed for their kind support and valuable technical guidance during the Research of this work.

### REFERENCES

- [1] Zhuo Zhang, Jiang Liu, Neetu Sara,Cherian, Ying Sun, Joo Hwee Lim, Wing Kee Wong,Ngan Meng Tan, Shijian Lu, Huiqi Li, Tien Ying Wong” *Convex Hull Based Neuro-Retinal Optic Cup Ellipse Optimization in Glaucoma Diagnosis*” 31st Annual International Conference of the IEEE EMBSMinneapolis, Minnesota, USA, September 2-6, 2009.
- [2] Huiqi Li, Opas Chutatape” *A Model- Based Approach for Automated Feature Extraction in Fundus Images*” Proceedings of the Ninth IEEE International Conference on Computer Vision (ICCV 2003) 2-Volume Set 0-7695-1950-4/03 \$17.00 © 2003 IEEE.
- [3] Archana Nandibewoor S B Kulkarni Sridevi Byahatti Ravindra Hegadi” *Computer Based Diagnosis of Glaucoma using Digital Fundus Images*” Proceedings of the World Congress on Engineering 2013 Vol III,WCE 2013, July 3 - 5, 2013, London, U.K..
- [4] Inoue, Kenji Yanashima, Kazushige Magatani, Takuro Kurihara, Naoto, “*Development Of A Simple Diagnostic Method For The Glaucoma Using Ocular Fundus Pictures*”, in the Proceedings of the 2005 IEEE Engineering in Medicine and Biology 27th Annual Conference Shanghai, China, September 1-4, 2005.
- [5] R’udiger Bock, J’org Meier, Georg Michelson, L’aszl’o G. Ny’ul, and Joachim Hornegger, “*Classifying Glaucoma with Image-Based Features from Fundus Photographs*”, DAGM 2007, LNCS 4713, pp. 355–364, 2007. Springer-Verlag Berlin Heidelberg 2007.
- [6] M muthu rama krishnan, oliver faust “*Automated glaucoma detection using hybrid feature extraction in retinal fundus images*” Journal of Mechanics in Medicine and Biology Vol. 13, No. 1 (2013) 1350011 (21 pages) © World Scientific Publishing Company DOI: 10.1142/S0219519413500115.
- [7] Vicente Grau, J. Crawford Downs, and Claude F. Burgoyne, “*Segmentation Of Trabeculated Structures Using An Anisotropic Markov Random Field: Application To The Study Of The Optic Nerve Head In Glaucoma*”, IEEE Transactions on Medical Imaging, Vol. 25, No. 3, March 2006. Pg.: 245.
- [8] U. Rajendra Acharya, Sumeet Dua, Xian Du, “*Automated Diagnosis of Glaucoma Using Texture and Higher Order Spectra Features*”, IEEE Transactions On Information Technology In Biomedicine, May 2011, pp 449-455.
- [9] Gopal Datt Joshi, Jayanthi Sivaswamy,“*Optic Disk and Cup Segmentation From Monocular Color Retinal Images for Glaucoma Assessment*”, IEEE Transactions On Medical Imaging, June 2011, pp. 1192-1205.
- [10] Jun Cheng, Jiang Liu, Beng Hai Lee, “*Closed Angle Glaucoma Detection in RetCam Images*”, IEEE Proceedings of the 32nd Annual International Conference, Sep 2004, pp 4096-4099.



- [11] Koen A. Vermeer, Frans M. Vos, Barrick Lo, "Modeling of Scanning Laser Polarimetry Images of the Human Retina for Progression Detection of Glaucoma", IEEE Transactions On Medical Imaging, May 2006, pp. 517-528
- [12] Mei-Ling Huang, Hsin-Yi Chen, Jian-Jun Huang: "Glaucoma detection using adaptive neuro-fuzzy inference system", Expert Systems with Applications 32 (2007) 458-468.
- [13] Yuji Hatanaka, Atsushi Noudo, Chisako Muramatsu, Akira Sawada, Takeshi Hara, Tetsuya Yamamoto, Hiroshi Fujita: "Vertical cup-to-disc ratio measurement for diagnosis of glaucoma on fundus images", Medical Imaging 2010: Computer-Aided Diagnosis. Proc. of SPIE Vol. 7624, 76243C.
- [14] L'aszl'o G. Ny'ul: "Retinal image analysis for automated glaucoma risk evaluation". MIPPR 2009: Medical Imaging, Parallel Processing of Images, and Optimization Techniques. Proc. of SPIE Vol. 7497.
- [15] Jyotika Pruthi, Dr.Saurabh Mukherjee:"Computer Based Early Diagnosis of Glaucoma in Biomedical Data Using Image Processing and Automated Early Nerve Fiber Layer Defects Detection using Feature Extraction in Retinal Colored Stereo Fundus Images", International Journal of Scientific & Engineering Research, Volume 4, Issue 4, April-2013.
- [16] M. Caroline Viola Stella Mary, B. Jainudhin Sudar Marri: "Automatic Optic Nerve Head Segmentation for Glaucomatous Detection using Hough Transform and Pyramidal Decomposition", International Conference on Recent Trends in Computational Methods, Communication and Controls (ICON3C 2012) Proceedings published in International Journal of Computer Applications (IJCA).
- [17] Sobia Nazi, Sheela N Rao: "Glaucoma Detection in Color Fundus Images Using Cup to Disc Ratio" The International Journal Of Engineering And Science (IJES) Vol. 3 Issue 6 Pages 51-58, 2014.
- [18] S. Sri Abirami, S.J Grace Shoba: "Glaucoma Images Classification Using Fuzzy Min-Max Neural Network Based On Data-Core", International Journal of Science and Modern Engineering (IJSME) ISSN: 2319-6386, Volume-1, Issue-7, June 2013.
- [19] S. Chandrika, K. Nirmala "Analysis of CDR Detection for Glaucoma Diagnosis", International Journal of Engineering Research and Applications (IJERA) ISSN: 2248-9622. NCACCT-19 March 2013.
- [20] Arturo Aquino, Manuel Emilio Gegúndez-Arias, and Diego Marin: "Detecting the Optic Disc Boundary in Digital Fundus Images Using Morphological Edge Detection and Feature Extraction Techniques", IEEE TRANSACTIONS ON MEDICAL IMAGING 2010.
- [21] N.Anil Kumar, M. Satya Anuradha, Prakash.SSVD.Vepa, Ravuri Daniel: "Active Contours Techniques for Automatic Detection of Glaucoma", International Journal of Recent Technology and Engineering (IJRTE) Volume-1, Issue-4, October 2012.
- [22] Chalinee Burana-Anusorn, Waree Kongprawechnon, Toshiaki Kondo, Sunisa Sintuwong and KanokvateTungpimolrut: "Image Processing Techniques for Glaucoma Detection Using the Cup-to-Disc Ratio", Thammasat International Journal of Science and Technology, Vol. 18, No. 1, January-March 2013.
- [23] Arulmozhivarman Pachiyappan, Undurti N Das, Tatavarti VSP Murthy and Rao Tatavarti: "Automated diagnosis of diabetic retinopathy and glaucoma using fundus and OCT images" Lipids in Health and Disease 2012, 11:73.
- [24] Preeti Kailas Suryawanshi: "An approach to glaucoma using image segmentation techniques" IJESRT 2(9): September, 2013.
- [25] K.Narasimhan, Dr.K.Vijayarekha: "An efficient automated system for glaucoma detection using fundus image", Journal of Theoretical and Applied Information Technology 2011.Vol. 33 No.1
- [26] Neelapala Anil Kumar and P.A.Nageswara Rao, Prof P.Mallikarjuna Rao, Smt. M. Satya Anuradha: "Automatic detection of glaucoma in eye by angle opens distance 500 calculation by using GUT", IJSAT (ISSN 2221-8386) Volume 1 No 6 August 2011.
- [27] Noor Elaiza Abdul Khalid, Noorhayati Mohamed Noor, Zamalia Mahmud, Saadiah Yahya, and Norharyati Md Ariff "Bridging Quantitative and Qualitative of Glaucoma Detection" World Academy of Science, Engineering and Technology Vol:6 2012-12-20.
- [28] Priya kumbhare, manisha Turkr and Rashmi kularkar "Computer Aided Automatic Glaucoma Diagnosis"International Journal of Electrical, Electronics and Data Communication, ISSN: 2320-2084 Volume-2, Issue-2, Feb.-2014.
- [29] Anantha Vidya Sagar ,S Balasubramanian and V.Chandrasekaran "Automatic Detection of Anatomical Structures in Digital Fundus Retinal Images" MVA2007 IAPR Conference on Machine Vision Applications, May 16-18, 2007,Tokyo, JAPAN .
- [30] Urja Zade and Prof. S. S. Lokhande" Retinal Image Glaucoma Detection using Optic Disk and Incremental Cup Segmentation" IJECCE Volume 5, Issue (4) July, Technovision-2014, ISSN 2249-071X.
- [31] S.Kavitha and K.Duraiswamy" An Efficient Decision Support System For Detection Of Glaucoma In Fundus Images Using Anfis" International Journal of Advances in Engineering & Technology, Jan 2012. IJAET ISSN: 2231-1963.
- [32] Asma Mansour, Jihene Malek and Rached Tourki "A Development of Computer-Aided Diagnosis Tools of vascular retinopathy using Fundus Images" International Conference on Control Engineering and Information Technology Proceedings Engineering and Technology Vol 1 PP 87-2,2013.
- [33] Sheeba O., Jithin George, Rajin P. K., Nisha Thomas, and Sherin George" Glaucoma Detection Using Artificial Neural Network" IACSIT International Journal of Engineering and Technology, Vol. 6, No. 2, April 2014.
- [34] Darsana S1, Rahul M Nair" A Novel Approach towards Automatic Glaucoma Assessment" International Journal of Scientific Research Engineering & Technology (IJSRET), ISSN 2278 - 0882 Volume 3, Issue 2, May 2014
- [35] S.Kavitha S.Karthikeyan and Dr.K.Duraiswamy"Neuroretinal rim Quantification in Fundus Images to Detect Glaucoma" IJCSNS VOL.10 No.6, June 2010.
- [36] S. Sekhar W. Al-Nuaimy and A. K. Nandi" Automated Localisation of Optic Disk and Fovea In Retinal Fundus Images" 16th European Signal Processing Conference (EUSIPCO 2008), Lausanne, Switzerland, August 25-29, 2008, copyright by EURASIP.
- [37] IK.Kavitha, IIM.Malathi "Optic Disc and Optic Cup Segmentation for Glaucoma Classification" International Journal of Advanced Research in Computer Science & Technology (IJARCS T) 2014).
- [38] Chalinee Burana-Anusorn, Waree Kongprawechnon, Toshiaki Kondo, Sunisa Sintuwong and KanokvateTungpimolrut" Image Processing Techniques for Glaucoma Detection Using the Cup-to-Disc Ratio" TIJSAT.
- [39] Subi. P .P" Glaucoma Screening Based On Super Pixel Classification and the Detection of Macula in Human Retinal Imagery" IJCAT, Volume 1, Issue 5, June 2014 ISSN: 2348 - 6090.
- [40] A.Iyyanarappan,G.Tamilpavai "Glaucomatous Image Classification Using Wavelet Based Energy Features and PNN" International Journal of Technology Enhancements and Emerging Engineering Research, Vol 2, ISSUE 4 85 ISSN 2347-4289.
- [41] www.glaucoma.org.
- [42] www.glaucomafoundation.org.
- [43] www.webmd.com